

Role of carotid body for neuronal protection in experimental subarachnoid haemorrhage

DeneySEL subaraknoid kanamada karotid cismin nöron korumasındaki rolü

Mehmet Dumlu Aydın¹, Nazan Aydın², Adnan Bayram³, Canan Atalay⁴, Sare Altaş⁵, Dilcan Kotan⁶, Hızır Ulvi⁷

ABSTRACT

Objective: Carotid bodies are known as main arterial chemoregulatory units. Despite well known that carotid bodies have an important role in cerebral circulation and blood pH regulation, their roles has not been investigated in subarachnoid haemorrhage. We investigated whether there is neuroprotective effect of neuron density of carotid bodies on the brain in subarachnoid haemorrhage.

Methods: Twenty hybrid rabbits were studied. Four of them were used as reference group (n=4) and the remaining was obliged to subarachnoid haemorrhage by injecting autologous blood into their cisterna magna (n=16) and sacrificed after one month. All carotid bodies and brains examined histopathologically using by stereologic methods. The relationship between the neuronal density of carotid body and degenerated neuron density of the hippocampus were compared statistically.

Results: Five rabbits with subarachnoid haemorrhage dead during the follow-up time (n=5). The average neuronal density of carotid body was 4500 ± 500 cells/mm³ and of hippocampus 170.000 ± 17.000 cell/mm³ in normal rabbit family. The degenerated neuron density of the hippocampus was 20.000 ± 3.000 cells/mm³ in rabbits with have high neuron density of carotid body and was 65.000 ± 8.000 cells/mm³ in rabbits with low neuron density of carotid body. The differences between the neuronal density of carotid body and the degenerated neuron numbers of the hippocampus were significant.

Conclusion: The neuron density of carotid body may play an important role on the protection of brain in subarachnoid haemorrhage.

Key words: Subarachnoid haemorrhage, carotid body, hippocampus, neurodegeneration, cerebral ischemia

ÖZET

Amaç: Karotid cisimler, temel arteriyel kemoregulator üniteler olarak bilinirler. Karotid cisimlerin serebral sirkülasyonda ve kan pH regülasyonunda önemli bir rolü olduğu iyi bilinmesine rağmen, subaraknoid kanamadaki rolleri henüz araştırılmamıştır. Biz subaraknoid kanamada karotid cisim nöron yoğunluğunun beyin üzerinde nöron koruyucu etkisinin olup olmadığını araştırdık.

Yöntemler: Yirmi hibrit tavşan çalışmada kullanıldı. Bunların dört tanesi (n=4) referans grup olarak kullanıldı ve kalanların (n=16) sisterna magna'ları içerisine otolog kan enjeksiyonu yapılarak subaraknoid kanama geliştirildi ve bir ay sonra hayvanların yaşam süresi sonlandırıldı. Tüm karotid cisim ve beyin dokuları, stereolojik metodlar kullanılarak histopatolojik olarak incelendi. Karotid cisimdeki nöronal yoğunluk ile hipokampustaki dejenere nöron yoğunluğu arasındaki ilişki istatistiksel olarak karşılaştırıldı.

Bulgular: Subaraknoid kanaması olan beş tavşan takip süresi içerisinde öldü (n=5). Normal tavşan ailesinde karotid cisim ortalama nöronal hücre yoğunluğu 4500 ± 500 /mm³ ve hipokampus ortalama nöronal hücre yoğunluğu 170.000 ± 17.000 /mm³ olarak saptandı. Karotid cisminde yüksek nöron yoğunluğu olan tavşanların hipokampuslarındaki dejenere nöron hücre yoğunluğu 20.000 ± 3.000 /mm³ iken karotid cisminde düşük nöron yoğunluğu olan tavşanların hipokampuslarındaki dejenere nöron hücre yoğunluğu 65.000 ± 8.000 /mm³ saptandı. Karotid cismin nöronal yoğunluğu ve hipokampusun dejenere nöron sayıları arasındaki farklılık istatistiksel olarak anlamlıydı.

Sonuç: Karotid cismin nöron yoğunluğu, subaraknoid hemorajide beyin dokusunun korunmasında önemli bir rol oynayabilir.

Anahtar kelimeler: Subaraknoid hemoraji, karotid cisim, hipokampus, nörodejenerasyon, serebral iskemii

¹ Ataturk University, Medical Faculty, Department of Neurosurgery, Erzurum, Turkey

² Ataturk University, Medical Faculty, Department of Psychiatry, Erzurum, Turkey

³ Ataturk University, Medical Faculty, Department of Cardiology, Erzurum, Turkey

⁴ Ataturk University, Medical Faculty, Department of Anesthesiology, Erzurum, Turkey

⁵ Ataturk University, Medical Faculty, Department of Pathology, Erzurum, Turkey

⁶ Sakarya University, Medical Faculty, Department of Neurology, Sakarya, Turkey

⁷ Ataturk University, Medical Faculty, Department of Neurology Erzurum, Turkey

Yazışma Adresi /Correspondence: Dilcan Kotan,

Department of Neurology, Medical Faculty, Sakarya University, Sakarya, Turkey Email: dilcankotan@yahoo.com

Geliş Tarihi / Received: 16.12.2012, Kabul Tarihi / Accepted: 10.01.2013

Copyright © Dicle Tıp Dergisi 2013, Her hakkı saklıdır / All rights reserved

INTRODUCTION

The carotid bodies (CB) are the most vascularised and chemosensitive structures in the body, CB are localised at the carotid bifurcation and supplied by mainly external and rarely internal carotid arteries. Cerebrovascular and cardiorespiratory autonomy are mainly regulated by neurochemical circuitry of CB. Glomus cells are chemosensitive units of the CB and they synaptically connected to glossopharyngeal nerve terminals. Glomus cells are very sensitive in the blood pH changes [1,2,3]. When the O₂ difference in the arteriovenous blood is less than 1%, CB are stimulated [4]. CB dysfunction can result in cerebral circulation disorders and cardiorespiratory disturbances [1]. Severe vasospasm induced by subarachnoid haemorrhage (SAH) can lead to decreased cerebral blood flow, disordered glucose metabolism, increased ischemia, decreased cerebral perfusion pressure, increased intracranial pressure, neuronal degeneration and early mortality [5,6,7]. If so, CB dysfunction can result in cerebral glucose metabolism disorders, cerebral circulation and cardio-respiratory disturbances and failure of body fluid pH regulation [8]. To examine whether the neuron density of CB has a role in the progression of SAH, neuron density of the CB and degenerated neuron density of the CA1 (cornu Ammon) region of the hippocampus were examined in SAH developed animals. The results shown that the low neuron density of CB may have an important role on the development of hippocampal neurodegeneration and worsened prognosis of SAH.

METHODS

Twenty hybrid rabbits were studied at two years old and weighing 3.5 ± 0.25 kg. Animal husbandry and the study design followed the guidelines of the National Institutes of Health. The study design was approved by the Committee on Animal Research at our university. Four of them were used to examine of normal stereologic anatomy of CB and hippocampus. The remainder animals (n=16) were anaesthetized by subcutaneous injection of a mixture of ketamine hydrochloride (25 mg/kg), lidocaine hydrochloride (15 mg/kg), and acepromazine (1 mg/kg). After preparing the occipito-cervical region, SAH was produced by the injection of 0.5cc blood

into cisterna magna taken from auricular veins. All animals were followed-up one month in the normal laboratory standards without treatment and all of them were sacrificed at the end of experiment. Their CB and brains were removed and preserved in 10% formalin solution for seven days. The specimens were embedded in paraffin blocks and consecutive twenty sections of 5 μ m of all preparations were taken for the stereological examinations. CB preparations were stained with hematoxyline and eosin (H&E). Hippocampus slices were stained with TUNEL staining for the detection of apoptosis. All preparations were observed light microscope and stereologic method were used for the determination of neuron numbers of the CB and CA1 regions of hippocampus.

Histopathologically, cytoplasmic condensation, nuclear shrinking, cellular angulations and pericytoplasmic halo formation secondary to cytoplasmic regression and Tunnel staining positivity were considered as the criteria of neuronal degeneration.

Physical dissector method was used to evaluate the numbers of neurons in CB and CA1. This method can easily estimate the particle number, be readily performed, intuitively simple, free from assumptions about particle shape, size and orientation, and unaffected overprotection and truncation. Data were obtained from dissector pairs, consisting of parallel sections taken at known intervals. Two labeled consecutive sections obtained from tissue samples (dissector pairs) were mounted on each slide. Twenty dissector pairs were taken in each block for analyse of neurons. A counting frame was placed on consecutive section photographs on screen of personal computer (PC) for counting of neurons. The bottom and the left hand edges of the frame were excluded for counting (exclusion) lines together with the extension lines. Other boundaries of the frame and the top-right corner were considered to be inclusion points and any particle which hit these lines or was located inside the frame counted as a dissector particle. Neurons of CB and CA1 regions were counted if they were visible in the reference section. Reference and look-up sections were reversed in order to double the number of dissector pairs without taking new sections (see Figure 1). The average numerical density of ganglial neurons (NvGN) per mm³ was estimated using the following formula.

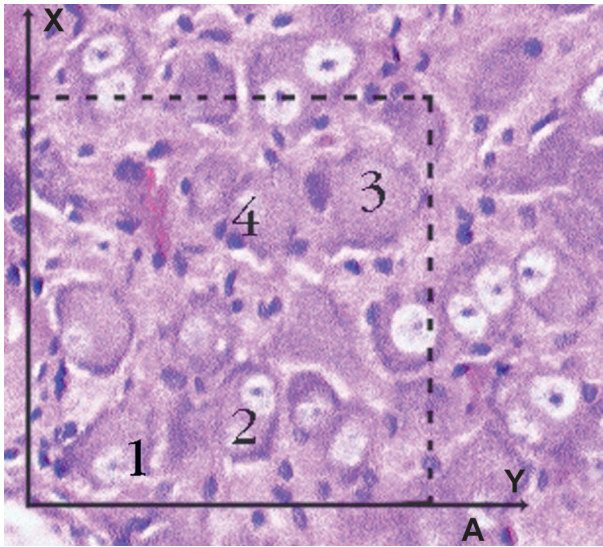


Figure 1. Histopathological appearance of a brain with subarachnoid haemorrhage (SAH) and is presented (BA: Basilar artery) (H&E x20, LM).

$$NvGN = \frac{\Sigma QN}{t \times A}$$

Where ΣQN is the total number of counted neurons appearing only in the reference sections; t is the section thickness and A is the area of the counting frame. Cavalieri volume estimation method was used to obtain the total number of neurons in each specimens. Total number of neurons was calculated by multiplication of the volume (mm^3) and numerical density of neurons in each CB or CA1 region.

To analyze the results, average neuronal numerical density of CB and CA1 region of all animals were accepted as mean values of normal rabbit family. The neuronal density of CB was higher than 5000 named as SAH-resistant group (GR) and less ones non resistant group (GNR). GR is the group

of damages less, has more carotid body density and consequently has less damage of cisterna magna and hippocampus. GNR is the group of damages more, has less carotid body density and consequently has more damage of cisterna magna and hippocampus.

The all dead animals were also included into the GNR. The neuron density of CB and degenerated neuron number of CA1 were compared statistically and results were analyzed with Mann-Whitney U Test.

RESULTS

Four of the sixteen rabbits died in the study group because of cardio-respiratory arrest during the follow-up period ($n=4$) and the others lived one month ($n=12$). The average neuronal density of CB was estimated as 4500 ± 500 cell/ mm^3 (Figure 2 A-B) and those of hippocampus 170.000 ± 17.000 cell/ mm^3 of normal rabbit family. In this classification, the degenerated neuron density of the CA1 was estimated as 20.000 ± 3.000 cell/ mm^3 in the GR (Figure 3) and 65.000 ± 8000 cells/ mm^3 in the GNR (Figure 4). The difference between the neuronal density of CB and degenerated neuron numbers of CA1 of the GR was significant ($p < 0.005$). But, the difference was more significant in GNR ($p < 0.0001$). The animals with high neuron density in their CB have good clinical outcome and low cerebral insult. The carotid bodies are responsible from regulate of blood and cerebrospinal fluid (CSF) pH, by means of glossopharyngeal nerve. High density of nerve regulates to blood chemistry better. A lot of carotid body nerve remains healthy in ischemic injury, exactly like this, increases to resistance of SAH.

Table 1. The average neuronal numerical density of neurons of CB and degenerated neuronal numerical density of CA1 region of the hippocampus

	GN	GR	GNR
Normal neuron density of B (cell/ mm^3)	4500 ± 500	>5000	<4000
Normal neuron density of hippocampus (cell/ mm^3)	170.000 ± 17.000	165.000 ± 9.000	130.000 ± 12.000
Degenerated neuron density of hippocampus (cell/ mm^3)	10 ± 2	5.000 ± 300	30.000 ± 3.000

CB: Carotid body, GN: Ganglial neurons, GR: SAH-resistant group, GNR: SAH-non resistant group SAH: Subarachnoid hemorrhage

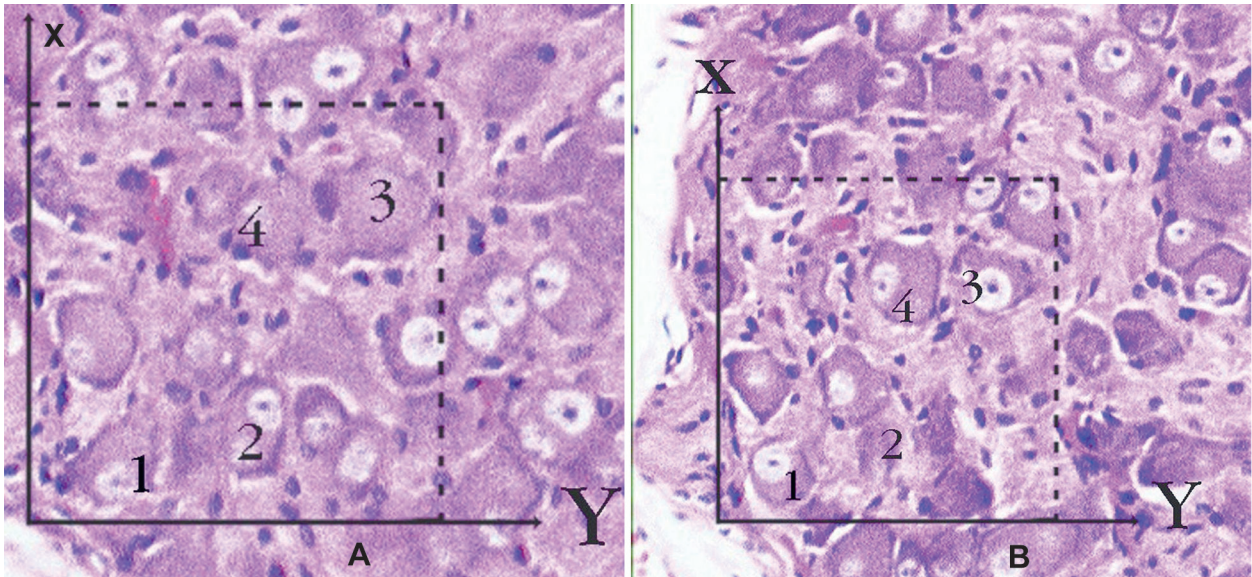


Figure 2 A-B. Application of the physical dissector method in which micrographs in same fields of view (A, B) are taken from two parallel adjacent thin sections separated by a distance of 5 μm in a normal rabbit. Upper and right lines of unbiased counting frames represent the inclusion lines and the lower and left lines including the extensions are exclusion lines. Any neuron nucleolus hitting the inclusion lines is excluded and nucleus profiles hitting the inclusion lines and located inside the frame are counted as dissector particles unless their profile extends up to the look-up section. The number of neurons from the two dissectors occurs in a volume given by the product of the counting frame area and distance between the sections. The numerical density of neurons is calculated from $N_V N = \sum Q-N / t \times A$. In this application, the nucleoli marked with '1, 3' are not dissector particles on A section as it disappeared section B. The nucleoli marked with '2, 4' are dissector particles on A section as it appeared section B (H&E x100, LM).

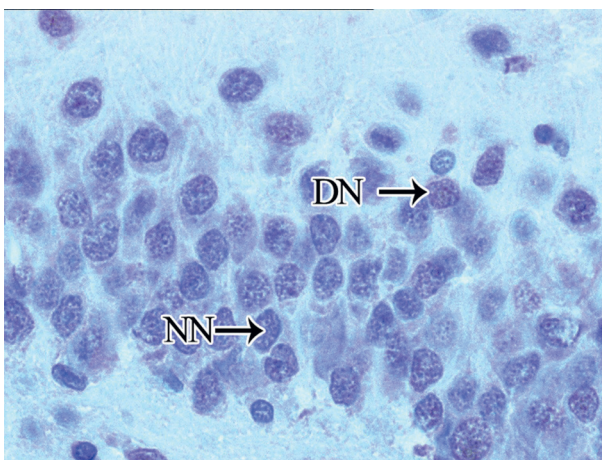


Figure 3. A histopathological appearance of CA1 region of a normal rabbit (NN: Normal neuron. Tunnel Staining, x100).

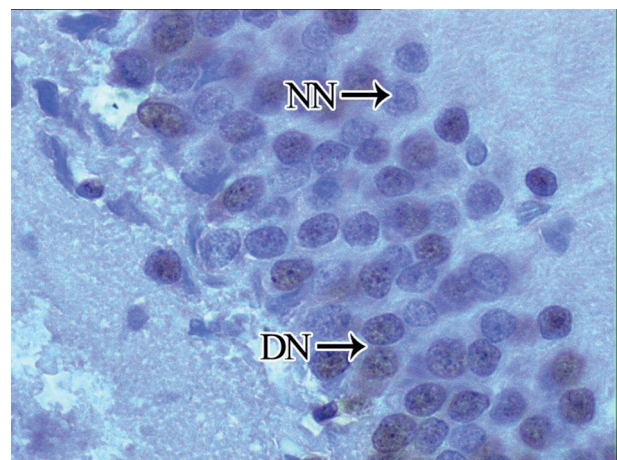


Figure 4. Considerable numbers of degenerated neurons as appear in brown colored (DN) are observed among the normal neurons (NN) in CA1 regions of hippocampus of the GNR. Both the nucleus and the cell body of neurons were shrunken and had lost much of their morphologic details (Tunnel Staining, x100).

DISCUSSION

The carotid body is the main arterial chemoreceptor with the characteristics of high blood flow, elevated metabolism, oxygen-sensing functions and susceptibility of arterial pH changes [4]. They have also vital functions for cerebrovascular and cardio-respiratory autoregulation [1,2]. Chemosensitive units of the CB are glomoid structures which formed by clusters of glomus cells located around the capillaries. Distal extensions of glomus cells are synaptically connected to petrosal ganglion neurons via glossopharyngeal nerve terminals and proximal ends connected to cardiorespiratory centers in the paraventricular nucleus of the hypothalamus [6]. In response to hypoxia, hypercapnia and blood pH changes glomus cells release appropriate neurotransmitters and stimulate paraventricular nucleus via neural networks of CB [3,4]. Vasoactive molecules produced by CB modulate the chemosensory processes body fluids pH and cerebral autoregulation. Doux et al reported that CB dysfunctions can result in cerebrovascular and cardiorespiratory autoregulation disorders [1]. Even, panic disorder and agoraphobia are presented with dyspnea and hyperventilation are the cardinal signs of a panic attack can be resulted from failure of CB alarm system. SAH develops due to various etiologic factors leading to tear of blood vessels in the subarachnoid spaces. Severely vasospasm triggering by SAH lead to acute cerebral ischemia, brain edema, blood-brain barrier disruption, increased intracranial pressure, decreased cerebral perfusion pressure and finally apoptotic degeneration of the brain. Disordered cerebral autoregulation is the most important dangerous factor in the progression of SAH [5]. Early cerebral vasoconstriction and diminished cerebral blood flow occur in the majority of subjects [9]. Severe SAH is associated with loss of cerebral autoregulation and cardiorespiratory irregularities [5]. Microvascular aggregation of red blood cells has also been accused of acute ischemic damage. Decreased CBF and decreased CPP are the most important factors in early mortality [10]. The mortality rate of SAH is about 25% within 24 hours and 45% at 30 days [11]. Extensive global ischemic brain damage can result in death shortly after severe SAH [8]. Vasoconstriction can lead to decreased cerebral blood flow and cerebral ischemia [12]. Profound elevation of intracranial pressure is an important fac-

tor in the development of cerebral ischemic damage in SAH [13]. Experimental SAH can be induced by autolog blood injection into the cisterna magna in animal models [11]. We also used the same method for observing clinical outcome and to examine if there was a relationship between the neuronal density of CB and degenerated neuron numbers of the CA1 region of hippocampus. Histopathological analyses were done by using stereologic methods [14,15,16]. Apoptotic degeneration at the CA₁ region was determined by TUNEL staining [17]. Some treatment methods directed to CB have been applied for reduce the complication of SAH. That the ischemic neuronal damage of the CB and brain may be recovered via early revascularization of the CB via posterior cerebral circulation in ischemic brain disease [18]. Intracerebral transplantation of CB can also ameliorate stroke-induced cerebral infarction [19]. CB receptors have a glucose sensing role in the blood entering the brain and integrating information about blood glucose levels by CB is essential for central nervous system metabolism. The nucleus tractus solitarius is an important relay station in central metabolic control and receives signals from peripheral glucose sensitive afferents from CB [20,21]. Chemoreceptors close to ventral surfaces of the medulla are responsive to CO₂ level and pH changes in the cerebrospinal fluid. Chemical informations coming from surfaces of medulla and CB are integrated together at the respiratory centers [22]. At this situation, sensibility of chemoreceptors can be change and chaotic state occur at the pH regulating centers. If so, CB have less neuron does not regulate adequately glucose metabolism, pH regulation and cerebral circulation. Insufficient CB can aggravate the ischemic insult generating effect of SAH. To decrease nerve in carotid body is result from secondary denervation injury to ischemic injury of glossopharyngeal nerve. High nerve density is regulates blood chemistry better. More carotid body remains healthy, exactly like this increases resistance of SAH. Ischemic injury of brain stem in SAH spoils to morphology and functions of carotid body. Exactly like this, pH of blood and CSF is spoiled. Because of that, ischemic injury grows and arises nerve death and finally brain death. Separately, it arises to vasodilatation of glossopharyngeal nerve. If there is a damage, cerebral vessels will arises to vasospasm.

In summary, this study in rabbits shows that the low neuron density of CB can be considered as a cause of the severity of neuronal degeneration in the hippocampus in SAH. Although the marked difference between the neuron density of CB and degenerated neuron number of hippocampus is thus unexplained, this difference may have important implications. CB have low neuron density may be important in both discontinuation of metabolic processes responsible for pH regulation in the body fluid and important decrease in vasoactive neurotransmitter production by glomus cells essential for the maintenance of glucose metabolism, cerebrovascular autoregulation. For reducing the dangerous effects of SAH on the brain, supportive interventions might be inquired toward to preserve of the CB structure and functions.

REFERENCES

- Doux JD, Yun AJ. The link between carotid artery disease and ischemic stroke may be partially attributable to autonomic dysfunction and failure of cerebrovascular autoregulation triggered by Darwinian maladaptation of the carotid baroreceptors and chemoreceptors. *Med Hypotheses* 2006;66:176-81.
- Kusakabe T, Matsuda H, Hayashida Y. Hypoxic adaptation of the rat carotid body. *Histol Histopathol* 2005;20:987-97.
- Rey S, Iturriaga R. Endothelins and nitric oxide: vasoactive modulators of carotid body chemoreception. *Curr Neurovasc Res* 2004;1:465-73.
- Oikawa S, Hirakawa H, Kusakabe T. Autonomic cardiovascular responses to hypercapnia in conscious rats: the roles of the chemo- and baroreceptors. *Auton Neurosci* 2005;117:105-14.
- Bederson JB, Germano IM, Guarino L. Cortical blood flow and cerebral perfusion pressure in a new noncraniotomy model of subarachnoid haemorrhage in the rat. *Stroke* 1995; 26:1086-91.
- Schultz HD, Sun SY. Chemoreflex function in heart failure. *Heart Fail Rev* 2000;5:45-56.
- De Toma G, Nicolanti V, Plocco M, et al. Baroreflex failure syndrome after bilateral excision of carotid body tumors: an underestimated problem. *J Vasc Surg* 2000; 31:806-10.
- Adams HPJ, Kassell NF, Torner JC. Early management of subarachnoid haemorrhage: A report of the Cooperative Aneurysm Study. *J Neurosurg* 1981;46:454-66.
- Naveri L, Stromberg C, Saavedra JM. Angiotensin IV reverses the acute cerebral blood flow reduction after experimental subarachnoid haemorrhage in the rat. *J Cereb Blood Flow Metab* 1994;14:1096-99.
- Bederson JB, Guarino L, Germano IM. Failure of changes in cerebral perfusion pressure to account for ischemia caused by subarachnoid haemorrhage: A new experimental model. *Soc Neurosci Abstr* 1994;20:224-8.
- Broderick JP, Brott TG, Duldner JE. Initial and recurrent bleeding are the major causes of death following subarachnoid haemorrhage. *Stroke* 1994;25:1342-47.
- Delgado TJ, Brismar J, Svendgaard NA. Subarachnoid haemorrhage in the rat: Angiography and fluorescence microscopy of the major cerebral arteries. *Stroke* 1985;16:595-602.
- Bederson JB, Levy AL, Ding WH, et al. Acute vasoconstriction after subarachnoid haemorrhage. *Neurosurgery* 1998;42:352-60.
- Cruz-Orive LM, Weibel ER. Recent stereological methods for cell biology: a brief survey. *Am J Physiol* 1990;258:148-56.
- Gundersen HJ, Bendtsen TF, Korbo L, et al. Some new, simple and efficient stereological methods and their use in pathological research and diagnosis. *APMI* 1988;96:379-94.
- Sterio DC. The unbiased estimation of number and sizes of arbitrary particles using the disector. *J Microsc* 1984;134:127-36.
- Ostrowski RP, Colohan RT. Mechanisms of hyperbaric oxygen-induced neuroprotection in a rat model of subarachnoid haemorrhage. *J Cerebral Blood Flow & Metabolism* 2005;25:554-71.
- Aydın MD, Ozkan U. Protective effect of posterior cerebral circulation on carotid body ischemia. *Acta Neurochir* 2002;144:369-72.
- Yu G, Fournier C, Hess DC. Transplantation of carotid body cells in the treatment of neurological disorders. *Neurosci Biobehav Rev* 2005;28:803-10.
- Unur E, Aycan K: Arteries of the carotid body in rats. *Anat Histol Embriol* 1999;28:167-69.
- Montero SA, Yarkov A, Lemus M, et al. Carotid Chemo-receptor Reflex Modulation by Arginine-Vasopressin Microinjected into the Nucleus Tractus Solitarius in Rats. *Archives of Medical Research* 2006;37:709-16.
- Berger AJ and Mitchel RA, Severinghaus JW. Regulation of respiration (first of three parts). *N Engl J Med* 1977;297:92-7.